

Comaneci-assisted coiling of wide-necked intracranial aneurysm: A single center preliminary experience

Gabriele Vinacci^{1,*}, Angelica Celentano², Edoardo Agosti³, Alberto Vito Terrana¹, Francesco Alberto Vizzari¹, Luca Nativo¹, Fabio Baruzzi¹, Antonio Tabano⁴, Davide Locatelli⁴ and Andrea Giorgianni¹.

¹ Neuroradiology Department Circolo Hospital, ASST Sette Laghi, 21100 Varese, Italy; gabriele.vinacci@asst-settelaghi.it (G.V.); albertovito.terrana@asst-settelaghi.it (A.V.T.); francescoalberto.vizzari@asst-settelaghi.it (F.A.V.); luca.nativo@asst-settelaghi.it (L.N.); fabio.baruzzi@asst-settelaghi.it (F.B.); andrea.giorgianni@asst-settelaghi.it (A.G.).

² Department of Radiology, University of Insubria, 21100 Varese, Italy; angelica_celentano@libero.it (A.C.)

³ Neurosurgery, Department of Medical and Surgical Specialties, Radiological Sciences and Public Health, University of Brescia, 25121 Brescia, Italy. edoardo_agosti@libero.it (E.A.)

⁴ Division of Neurosurgery, Department of Biotechnology and Life Sciences, University of Insubria, 21100 Varese, Italy; antonio.tabano@asst-settelaghi.it (A.T) davide.locatelli@asst-settelaghi.it (D.L.)

* Correspondence: gabriele.vinacci@asst-settelaghi.it; Tel.: +39-0332-278353

Abstract: *Background:* Wide-necked aneurysms are still challenging both for coiling and microsurgical clipping. They often require additional techniques to prevent coil prolapse into the parent artery, such as balloon-assisted and stent-assisted coiling. Comaneci is an expandable and removable stent that acts as a bridging device and does not interfere with the blood flow of the parent artery. *Methods:* We retrospectively reviewed our institutional radiological and clinical chart of the patients treated for saccular intracranial aneurysm via endovascular coiling Comaneci-assisted. The aim of the study is to report our preliminary experience in Comaneci-assisted coiling of wide-necked intracranial aneurysms. *Results:* We included 14 patients, 11 with a ruptured intracranial aneurysm, that were treated with Comaneci-assisted coiling. Five minor intraprocedural complications and 2 intraprocedural failure of the device were registered. At one year follow-up a satisfying aneurysm occlusion has been observed in 85% of the cases. *Conclusion:* Even if long-term follow-up data and larger case series are needed, this preliminary study showed the feasibility of the Comaneci-assisted coiling for both ruptured and unruptured wide-neck intracranial aneurysms, with similar occlusion rate to balloon-assisted coiling. However we registered high incidence of thromboembolic complications probably related to the lack of heparin administration. The main advantage of this technique is likely in cases of ruptured intracranial aneurysms, as there is no need for post-procedural antiplatelet therapy.

Citation: Lastname, F.; Lastname, F.; Last-name, F. Title. *J. Clin. Med.* **2021**, *10*, x. <https://doi.org/10.3390/xxxxx>

Received: date

Accepted: date

Published: date

Publisher's Note: MDPI stays neutral with regard to jurisdictional claims in published maps and institutional affiliations.

Keywords: Comaneci; assisted-coiling; intracranial aneurysm; embolization



Copyright: © 2020 by the authors. Submitted for possible open access publication under the terms and conditions of the Creative Commons Attribution (CC BY) license (<http://creativecommons.org/licenses/by/4.0/>).

1. Introduction

Even if endovascular treatment of intracranial aneurysms has been widely performed for both ruptured and unruptured intracranial aneurysms [1–3] supporting and replacing surgical treatment, wide-necked aneurysms (WNAs) are still a challenging morphological type of aneurysm.

The endovascular coiling for WNAs is associated with a high risk of coil mass protrusion into the parent vessel and consequent ischemia of the downstream territories [4]. Indeed, in comparison with narrowed-neck aneurysms, endovascular embolization of WNAs is associated to higher procedural risks and poorer long-term follow-up [4]. To

avoid coil prolapse and major ischemic iatrogenic complications, WNAs usually require additional techniques, such as balloon-assisted coiling (BAC), stent-assisted coiling (SAC), or the application of a flow diverter stent or the emerging endosaccular devices [5-8]. These additional techniques may increase the risk of thromboembolic complications during the procedure and, in certain cases, require dual antiplatelet therapy [9-11]. Both BAC and SAC are currently implied in the treatment of WNAs to protect the parent vessel in either a temporary or permanent fashion [12,13]. However, BAC temporarily obstructs flow, meanwhile the use of stents necessitates dual antiplatelet therapy that increases procedural as well as long-term bleeding risks [14,15].

We describe our early experience with Comaneci bridging device in the treatment of both ruptured and unruptured WNAs. The main advantage of this novel technique is the possibility to perform a temporary bridging on the neck aneurysms without the blood flow occlusion and its intrinsic soft structure may reduce the risk of vessel rupture, compared to the remodeling balloons, and it does not required dual antiplatelet therapy (DAPT), as a self-expanding stent, as it is fully removable.

The aim of the study is to retrospectively describe our early experience with Comaneci bridging device in the treatment of both ruptured and unruptured WNAs in 14 patients.

2. Methods

This is a monocentric study. We retrospectively collected the patients with WNAs treated for saccular intracranial aneurysm via endovascular Comaneci-assisted coiling. We collected patients since our first institution case in October 2015 and May 2021. The Comaneci-assisted coiling was performed by two senior operators of 12 and 6-year of experience at the moment of the end of the enrollment. The Comaneci (Rapid Medical, Yokneam, Israel) bridging device is a controllable, nondetachable, and retrievable temporary bridging device recently introduced to assist in the coiling process [16–19]. As a bridging device, the Comaneci does not interfere with the blood flow of the parent artery and it can be expanded according to the aneurysm neck morphology and vessel requirement [17]. The Comaneci device consists of three device models: Comaneci, Comaneci Petit, and Comaneci 17 which are adaptable respectively for vessel diameters of 1.5 - 4.5 mm, 1.5 - 3.5 mm and 0.5 - 3 mm. The device consists of a nitinol fine wire mesh region at the distal end mounted on a flexible shaft that expands and contracts directly when the handle with a control slider is opened and closed. The wires of the mesh are radiopaque, which allows great visibility under fluoroscopy. The Comaneci has a flexible and soft distal tip which allows safe navigation into the vessel.

WNAs have been defined as an aneurysm with an absolute neck width >4 mm or a dome-to-neck ratio of <2 mm. All medical records and imaging were revised. The neurological assessments at discharge and at 3-months follow-up were evaluated by modified Ranking scale (mRS). 3-months magnetic resonance imaging and 1- year digital subtraction angiography was performed. The Modified Raymond-Roy Occlusion Classification was used to classify the aneurysmal status.

The primary goals of our retrospective collection were to assess the safety of Comaneci measured by the number of complications after the procedure; the efficacy of Comaneci, measured by the required deployment of a stent or the need of microsurgical conversion; the thromboembolic risk evaluated as the number of intraprocedural thromboembolic events.

Antiplatelet and antithrombotic management

The protocol of antiplatelet and anticoagulant medications was variable depending on the SAH. Prior 100 mg Acetylsalicylic acid and 75mg/day Clopidogrel, for 5 days before the endovascular embolization, were provided for patients with unruptured aneurysms (in anticipation in case of treatment failure and permanent stent placement

needing). The DAPT was discontinued after the procedure if the Comaneci-assisted embolization was successful. Among the patients with ruptured aneurysms, no preventive antiplatelet therapy was provided. In both cohorts, according to our institution protocol, no intravenous heparin was administered, all the catheters were continuously perfused with saline infused with heparin (1500 UI/L), no intravenous heparin was infused. In our institution we prefer continuous flushing of the catheters with heparin during aneurysm embolization that, according to our experience, reduces the risk of clot formation inside the catheters.

Endovascular procedure

All the procedures were performed through right femoral artery access. Through a 7F catheter placed in ICA or Vertebral artery, two microcatheters were used: one 0.017" microcatheter for aneurysm catheterization and one 0.021" or 0.017" microcatheter for the positioning of the Comaneci in the parent artery.

In all cases a three-dimensional rotational angiography (3D-DSA) was performed and the images were evaluated to determine the correct coils and Comaneci size.

First a 0.021" microcatheter, for the Comaneci and Comaneci Petit, or a 0.017" microcatheter, for Comaneci 17, was navigated in the parent artery, then a 0.017" microcatheter was navigated in the aneurysm sack (Figure 1). The Comaneci was then open until a satisfying neck bridging was obtained and the coil was then positioned into the sack (Figure 1). Before the detachment of every coil, the Comaneci was close to evaluate the stability, the correct intrasaccular disposition of the coils, and to exclude the embedding of the coils through the Comaneci. A post-procedural CT was performed in every patient to exclude any periprocedural complication.

3. Results

Population

We included 14 patients diagnosed with saccular intracranial aneurysms who received Comaneci-assisted endovascular coiling. Nine (64%) were female and the mean age was 62.3 years (range 45-86 years) (Table 1).

Eleven (79%) patients were admitted with subarachnoid hemorrhage (SAH), 1 (7%) patient had a persistent headache, 1 (7%) patient had a post clipping growing neck remnant, and 1 (7%) patient was occasionally diagnosed during magnetic resonance imaging (MRI) screening for familiarity. Seven aneurysms (50%) were of the anterior communicating artery (ACom), 5 (36%) of the communicating internal carotid artery (ICA), 1 (7%) in the anterior medullary segment of the posteroinferior cerebellar artery (PICA) and 1 (7%) in the middle cerebral artery (MCA). The mean aneurysm height was 5.83 mm (range 2-14.5 mm), and the mean maximal width was 4.33 mm (range 2-15.6 mm), with mean neck size of 3.14 mm (range 2-8.2 mm).

Case	Age	Sex	Location	SAH	Max size (height, width, neck) mm	Device	Complications	Rescue treatment	mRR	3-months mRs
1	74	F	PCOM	No	4.2, 7, 4	Comaneci	-		I	0
2	65	M	PCOM	Yes	3.1, 4, 3	17	-		I	0
3	70	F	PICA	Yes	3.5, 2, 1.5	Comaneci	-		I	0
4	86	F	PCOM	Yes	6.4, 4.3, 5.5	Comaneci	Intra-Comaneci and parent artery clot formation	Stent	II	6

5	59	F	ACOM	Yes	10, 6.2, 5.5	17	-		II	0
6	65	F	PCOM	No	6.7, 3.9, 3	Petit	-		II	0
7	51	F	MCA	No	2, 2.2, 2	Petit	-		II	5
8	65	M	ACOM	Yes	5.7, 3.7, 3.5	17	-			0
9	77	F	PCOM	Yes	8, 10.3, 5.9	Comaneci	Intra-Comaneci clot formation		I	0
10	65	F	ACOM	Yes	3, 2.4, 2	17	-		I	5
11	45	M	ACOM	Yes	5.5, 3.6, 2.8	17	Intra-Comaneci clot formation		III b	1
12	62	F	ACOM	Yes	9, 4.5, 3	17	Intra-Comaneci clot formation	Stent	III b	0
13	55	M	ACOM	Yes	14.5, 15.6, 8.2	17	-		I	0
14	61	M	ACOM	Yes	3, 5.9, 5	17	Intra-Comaneci clot formation		II	0

Table 1. Included patients ordered chronologically. Demographic characteristics of the patients and aneurysm characteristics, device used and operative outcome. ACOM, anterior communicating artery; PICA, posterior inferior cerebellar artery; MCA, middle cerebral artery; PCOM, posterior communicating artery.

138
139
140
141
142

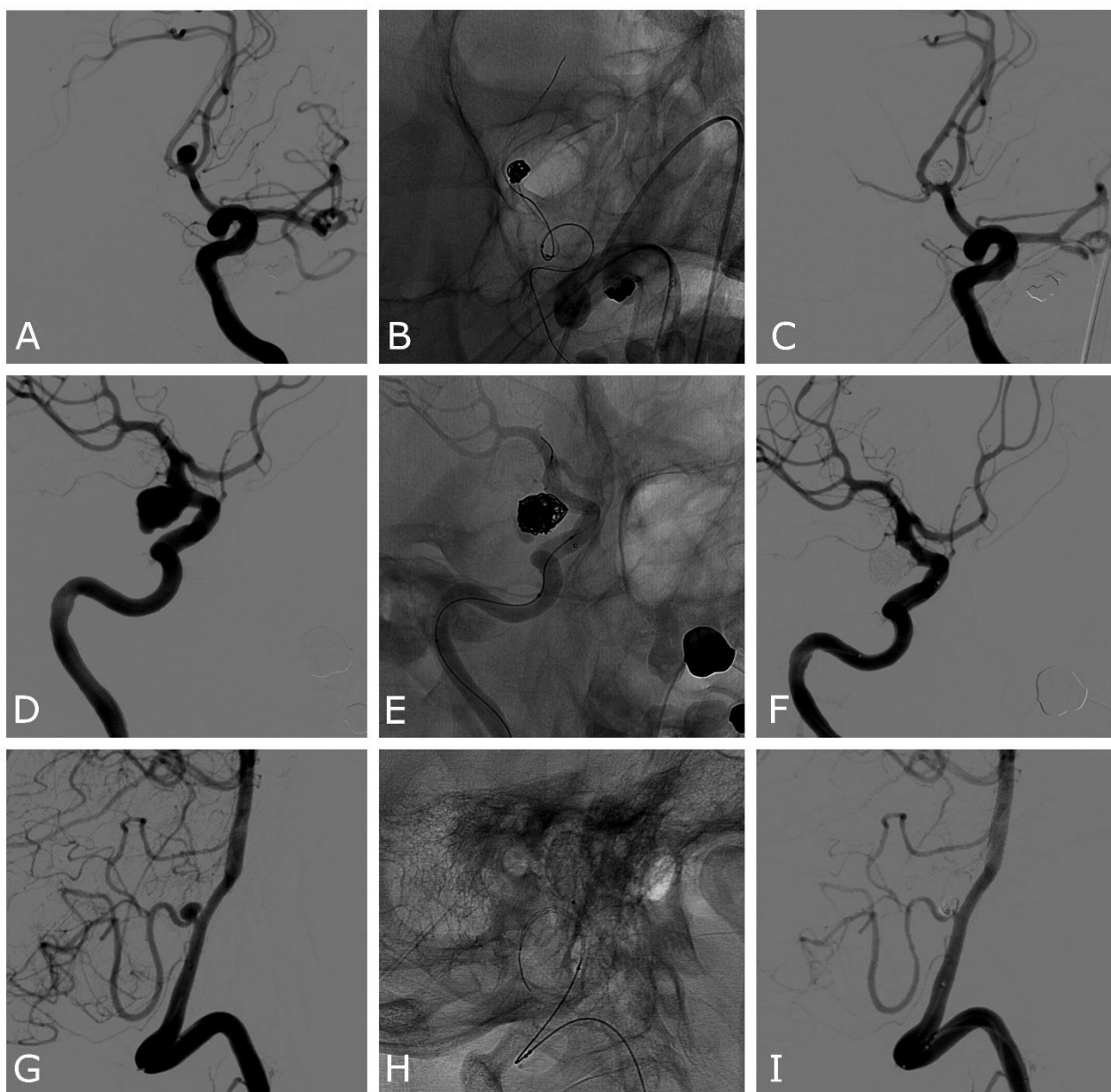


Figure 1. Patient number 13(A, B, C): ruptured ACOM wide-neck aneurysm. A) Anteroposterior oblique 2D DSA demonstrating the ACOM aneurysm with a daughter sac pointing superiorly. B) Unsubtracted image showing the expanded Comaneci after the first framing coil is deployed. C) DSA final result demonstrating complete occlusion of the aneurysm and patency of both the ACA. Patient number 5 (D, E, F): unruptured PCOM wide-neck aneurysm. D) Lateral oblique 2D DSA demonstrating the PCOM aneurysm. E) Unsubtracted image showing the expanded Comaneci after the first framing coil is deployed. F) DSA final result demonstrating near-complete occlusion of the aneurysm, with a small neck remnant in the inferior part and patency of ICA. Patient number 3 (G, H, I): ruptured PICA wide-neck aneurysm. G) Lateral oblique 2D DSA demonstrating the PICA aneurysm. H) Unsubtracted image showing the expanded Comaneci and the 0.017" microcatheter in the aneurysm sack. I) DSA final result demonstrating complete occlusion of the aneurysm, with a small neck remnant in the inferior part and patency of PICA. DSA, digital subtracted angiography; PCOM, posterior communicating artery; ICA, internal carotid artery; ACA, anterior cerebral artery; ACOM, anterior communicating artery; PICA, posterior inferior cerebellar artery.

We deployed 4 (29%) standard Comaneci, 8 (57%) Comaneci 17 and 2 (14%) Comaneci Petit. No navigation or deployment problems have been observed. In 12 (86%) patients Comaneci was able to be deployed to successfully bridge the aneurysmal neck, in 2 (14%)

143

144

145

146

147

148

149

150

151

152

153

154

155

156

157

158

159

160

patients Comaneci did not perform a satisfying scaffolding on the neck of the aneurysm and a self-expandable stent was required.

Modified Raymond-Roy Occlusion Classification (Table 1) achieved at the final angiographic images was Class I in 6 (43%) cases; Class II in 5 (36%) cases and Class IIIb in 2 (14%) cases. No migration of the Comaneci was observed during its expansion or vasospasm in the parent artery. In all the cases an excellent visualization of the device was observed.

Complications

At least an intraprocedural complication was observed in 5/14 patients (35%) (Table 1). In 3/14 (21%) cases we observed clot formation inside the mesh of Comaneci (Figure 2), rapidly regressing to the administration of 500mg of Acetylsalicylic acid and Tirofiban (dose by weight, bolus infusion in 30 minutes followed by 12 hours infusion). In 2/14 (14%) cases after infusion of 500mg Acetylsalicylic acid and Tirofiban by scheme the deployment of a rescue Atlas stent (Stryker Neurovascular, Salt Lake City, UT, USA) (Figure 2) was necessarily followed by 1 month of DAPT and subsequent 3 months of Acetylsalicylic acid 100mg/die. In one of the cases where a rescue Atlas stent was released, we had a failure of the Comaneci which was not able to perform a sufficient scaffold on the aneurysm neck and, during the attempt of embolization, we observed intra-Comaneci clot formation and a SAC was immediately performed. In the other case the Comaneci-assisted embolization was performed but coils protruded on the aneurysm neck and intra-Comaneci clot formation was observed, we than the released an Atlas stent to ensure the parent vessel patency. Notably all the complications reported occurred in ruptured aneurysms in which no antiplatelet drugs were administered before the embolization.

In all cases, at imaging follow-up no ischemia was observed documented by strict CT follow-up for at least 30 days after the embolization. No intraprocedural bleeding or delayed aneurysm bleeding was observed.

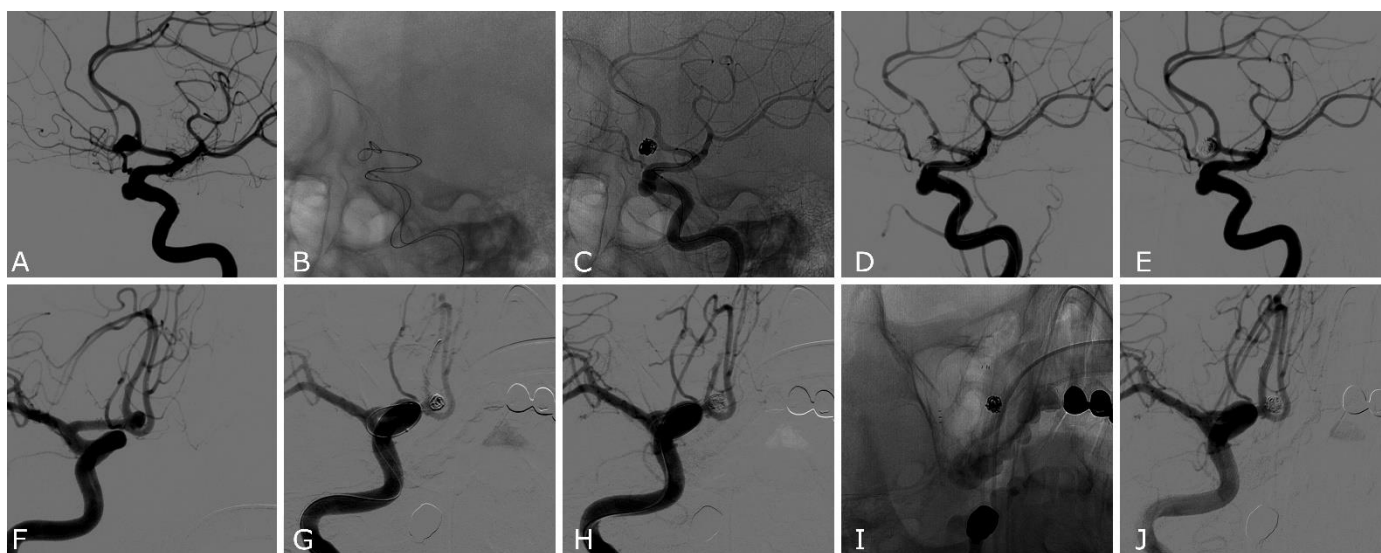


Figure 2 Patient number 11 (A, B, C, D, E): ruptured ACOM wide-neck aneurysm. A) Lateral oblique 2D DSA demonstrating the ACOM aneurysm with a daughter sac pointing anteriorly. B, C) Unsubtracted image showing the expanded Comaneci during the coiling. D) Lateral oblique 2D DSA showing the clot formation between the meshes of Comaneci that required the infusion of Acetylsalicylic acid and Tirofiban. E) Lateral oblique 2D DSA acquired 30 minutes after the infusion of Acetylsalicylic acid and Tirofiban demonstrating a complete resolution of the thrombotic complication and a neck remnant of the aneurysm. Patient number 12 (F, G, H, I, J): ruptured ACOM wide-neck aneurysm. F) Anteroposterior oblique 2D DSA demonstrating the ACOM aneurysm. G) Anteroposterior oblique 2D DSA demonstrating clot formation between the meshes of Comaneci that required infusion of Acetylsalicylic acid and Tirofiban. H) Anteroposterior oblique 2D DSA after

removing the Comaneci showing the protrusion of the coils in the parent artery and thromboembolic occlusion of the right A2 segment of anterior cerebral artery not yet responsive to medical treatment. I) Unsubtracted image of the deployment of a rescue Atlas stent. J) Anteroposterior oblique 2D DSA acquired 30 minutes after the infusion of Acetylsalicylic acid and Tirofiban, demonstrating the patency of the Atlas stent, the resolution of the clot and the patency of both anterior cerebral arteries.

Follow-up

In a range between 12 and 18 months, DSA follow-ups were performed, 10 (71%) patients had a complete aneurysm occlusion, 2 (14%) had a small neck remnant that did not require any further endovascular or microsurgical intervention, 1 (7%) had revascularization of the aneurysm sack and required the deployment of a flow diverter stent (FDs). 13/14 (93%) patients had 3 and 6 months CT that demonstrated no delayed aneurysm bleeding and the appearance of acute or chronic ischemic lesions. Clinical status at 3-months, assessed by mRs we observed good outcome (mRs 0-2) in 11 (79%) patients, poor outcome (5-6) in 3 (21%) patients (Table 1). Among the patients with poor outcome 2 had a ruptured intracranial aneurysm and developed severe intracranial vasospasm, 1 patient had a pretreatment mRs of 5 and no worsening of mRs was observed.

4. Discussion

Despite our preliminary experience, our results show the feasible use of Comaneci device as a temporary bridging device in the coil-assisted treatment of WNAs. Since its approval Comaneci device has been implied in different modalities and different cerebrovascular pathologies [20-22].

Comaneci-assisted embolization ranks between BAC and SAC. Both for BAC and SAC, the aim is to assist the coils' deployment while preventing coils' herniation into the parent vessel [23,24]. BAC involves the temporary vessel occlusion by the inflation of the balloon across the neck of an aneurysm, while SAC involves the placement of a self-expanding stent to support the coils across an aneurysm neck [24]. Although both methods have been demonstrated safe and efficient, BAC may be preferable in some clinical situations because it does not routinely require antiplatelet therapy, [23] although in tortuous anatomy the navigability of the balloon may be a limit. The Comaneci-assisted coiling owns both BAC and SAC characteristics: it has the advantage to perform a temporary bridging effect as the balloon avoids the flow occlusion as a self-expanding stent. These advantages may induce a lower risk of thromboembolic events, in addition its intrinsic soft structure may reduce the risk of vessel rupture during the assisted embolization compared with balloons that present a stiffer structure. However, a potential limitation of the Comaneci is the impossibility to block the blood flow in the event of an intraprocedural rupture. Although Comaneci does not require antiplatelet therapy, it has been described its tendency to clot formation. Sikarov et al. [25] demonstrated an incidence of 5.93% intra-Comaneci clot formation all rapidly regressing with abciximab infusion. Molina-Neuvo et al. [26] and Fisher et al. [17] observed respectively 1.7% and 7.1% of clot formation. In our initial experience, although we experience 35% clot formation. The higher incidence we observed, compared with the previous studies [16, 18, 19, 25], may be related to the lack of intravenous heparin administration. We observed thrombotic complications only in the group of ruptured aneurysms, in which neither antiplatelet nor anticoagulant were administered; meanwhile in the unruptured group, in which DAPT was previously administered, no thromboembolic complication occurred. We believe that intravenous heparin administration may reduce the incidence of thrombotic complications as it may reduce platelet activation on the Comaneci meshes. Although we observed thrombotic complications in 5 patients, rapidly regressing after medical therapy, no ischemic lesion had been demonstrated during the first month follow-up strict CT and clinical follow-up, except in one patient where severe and unresponsive diffuse intracranial vasospasm occurred. Although we were not able to perform an MRI and we might have underestimated the

ischemic lesions, all the patients did not reported any symptoms related to the complications. While it has been observed the risk of embedding the coil through the Comaneci meshes [18,26], we did not observe it in any procedure. This risk may be reduced by closing the Comaneci before the detachment of every coil and, if a protrusion of the coils has been observed, the recovery of the coil and a new deployment is mandatory. We observed a satisfying occlusion rate of 86% at follow-up. This rate is similar compared with BAC but lower compared with SAC [27–29]. However, in our series we observed a higher rate of complication than BAC and SAC [27–29] this may be related to our early experience and the small cohort. Compared to our experience with other embolization techniques in ruptured WNAs such as SAC and FDs we observed a higher incidence of thromboembolic complication with Comaneci-assisted coiling. In our experience the incidence of thromboembolic complication with SAC is 6% and 11% with FDs however the rebleeding rates were higher in both groups, 8% and 11% respectively. Compared with the aforementioned techniques we observed a higher incidence of thromboembolic complication with Comaneci but we did not experience any rebleeding. The real advantage of Comaneci compared with a self-expandable stent is the no needing of antiplatelet therapy that, especially in ruptured intracranial aneurysm, may reduce the severity of a possible rebleeding and allows a safer clinical and neurosurgical management of SAH.

In agreement with the results of this study, the Comaneci-assisted coiling is a feasible technique in case of wide-necked intracranial aneurysm. Although in our study we demonstrated an unclear safety of the procedure, given the high incidence of thrombotic complication. We believe to avoid and reduce this risk, according to the previous studies, anticoagulation is mandatory especially in ruptured aneurysms. However studies with a greater number of cases are needed to support the preliminary evidence that emerged in this study and to define more clearly the possible periprocedural complications. The best application of this technique is likely in cases of ruptured intracranial aneurysms, as there is no need for post-procedural antiplatelet therapy.

Limitations

The main limitations of this study are its retrospective nature, with a small number of patients and lack of long-term follow-up. Furthermore, the absence of a BAC control group limits our ability to extrapolate the efficacy of Comaneci-assisted coiling.

Author Contributions: : Conceptualization, A.G. and G.V.; Methodology, A.G., G.V., A.C. and E.A.; Validation, A.G., G.V., A.C., E.A.; A.V.T, F.A.V., L.N., F.B. and D.L.; Formal Analysis, A.G., G.V., A.C. and E.A.; Investigation, A.G., G.V. and A.C.; Data Curation, A.G., G.V. and A.C.; Writing—Original Draft Preparation, A.G., G.V., A.C. and E.A; Writing—Review & Editing, A.G., G.V., A.C., E.A Visualization, .G., G.V., A.C., E.A.; A.V.T, F.A.V., L.N., F.B. and D.L; Supervision, A.G., D.L and F.B.; Project Administration, A.G. and G.V. All authors have read and agreed to the published version of the manuscript.

Funding: Kardia SRL supported submission costs.

Institutional Review Board Statement: Not applicable.

Informed Consent Statement: Informed consent was obtained from all subjects involved in the study.

Data Availability Statement: No new data were created or analyzed in this study. Data sharing is not applicable to this article.

Conflicts of Interest This research received no external funding.

References

1. Molyneux AJ, Kerr RS, Yu LM, Clarke M, Sneade M, Yarnold JA, Sandercock P; International Subarachnoid Aneurysm Trial (ISAT) Collaborative Group. International subarachnoid aneurysm trial (ISAT) of neurosurgical clipping versus endovascular coiling in 2143 patients with ruptured intracranial aneurysms: a randomised comparison of effects on survival, dependency,

- seizures, rebleeding, subgroups, and aneurysm occlusion. *Lancet*. **2005** Sep 3-9;366(9488):809-17. doi: 10.1016/S0140-6736(05)67214-5. PMID: 16139655. 300
2. Peng C, Diao YH, Cai SF, Yang XY. Endovascular coiling versus microsurgical clipping for ruptured intracranial aneurysms: a meta-analysis and systematic review. *Chin Neurosurg J*. **2022** Jul 25;8(1):17. doi: 10.1186/s41016-022-00283-3. PMID: 35879784; PMCID: PMC9310462. 302
3. Zhu W, Ling X, Petersen JD, Liu J, Xiao A, Huang J. Clipping versus coiling for aneurysmal subarachnoid hemorrhage: a systematic review and meta-analysis of prospective studies. *Neurosurg Rev*. **2022** Apr;45(2):1291-1302. doi: 10.1007/s10143-021-01704-0. Epub 2021 Dec 6. PMID: 34870768; PMCID: PMC8976818. 305
4. Mascitelli JR, Lawton MT, Hendricks BK, Nakaji P, Zabramski JM, Spetzler RF. Analysis of Wide-Neck Aneurysms in the Barrow Ruptured Aneurysm Trial. *Neurosurgery*. **2019** Nov 1;85(5):622-631. doi: 10.1093/neuros/nyy439. PMID: 30346618. 308
5. Arthur AS, Molyneux A, Coon AL, Saatci I, Szikora I, Baltacioglu F, Sultan A, Hoit D, Delgado Almandoz JE, Eljovich L, et al. The safety and effectiveness of the Woven EndoBridge (WEB) system for the treatment of wide-necked bifurcation aneurysms: final 12-month results of the pivotal WEB Intracranial Therapy (WEB-IT) Study. *J Neurointerv Surg*. **2019** Sep;11(9):924-930. doi: 10.1136/neurintsurg-2019-014815. Epub 2019 Apr 16. PMID: 30992395; PMCID: PMC6824604. 311
6. Bhogal P, Lylyk I, Chudyk J, Perez N, Bleise C, Lylyk P. The Contour-Early Human Experience of a Novel Aneurysm Occlusion Device. *Clin Neuroradiol*. **2021** Mar;31(1):147-154. doi: 10.1007/s00062-020-00876-4. Epub 2020 Jan 28. PMID: 31993679. 315
7. Chancellor B, Raz E, Shapiro M, Tanweer O, Nossek E, Riina HA, Nelson PK. Flow Diversion for Intracranial Aneurysm Treatment: Trials Involving Flow Diverters and Long-Term Outcomes. *Neurosurgery*. **2020** Jan 1;86(Suppl 1):S36-S45. doi: 10.1093/neuros/nyz345. PMID: 31838533. 317
8. Becske T, Potts MB, Shapiro M, Kallmes DF, Brinjikji W, Saatci I, McDougall CG, Szikora I, Lanzino G, Moran CJ, et al. Pipeline for uncoilable or failed aneurysms: 3-year follow-up results. *J Neurosurg*. **2017** Jul;127(1):81-88. doi: 10.3171/2015.6.JNS15311. Epub 2016 Oct 14. PMID: 27739944. 320
9. Ryu CW, Park S, Shin HS, Koh JS. Complications in Stent-Assisted Endovascular Therapy of Ruptured Intracranial Aneurysms and Relevance to Antiplatelet Administration: A Systematic Review. *AJNR Am J Neuroradiol*. **2015** Sep;36(9):1682-8. doi: 10.3174/ajnr.A4365. Epub 2015 Jul 2. PMID: 26138136; PMCID: PMC7968784. 323
10. Bodily KD, Cloft HJ, Lanzino G, Fiorella DJ, White PM, Kallmes DF. Stent-assisted coiling in acutely ruptured intracranial aneurysms: a qualitative, systematic review of the literature. *AJNR Am J Neuroradiol*. **2011** Aug;32(7):1232-6. doi: 10.3174/ajnr.A2478. Epub 2011 May 5. PMID: 21546464; PMCID: PMC7966042. 326
11. Pierot L, Cognard C, Spelle L, Moret J. Safety and efficacy of balloon remodeling technique during endovascular treatment of intracranial aneurysms: critical review of the literature. *AJNR Am J Neuroradiol*. **2012** Jan;33(1):12-5. doi: 10.3174/ajnr.A2403. Epub 2011 Feb 24. PMID: 21349960; PMCID: PMC7966153. 329
12. Brinjikji W, Cloft HJ, Kallmes DF. Difficult aneurysms for endovascular treatment: overwide or undertall? *AJNR Am J Neuroradiol*. **2009** Sep;30(8):1513-7. doi: 10.3174/ajnr.A1633. Epub 2009 May 20. PMID: 19461057; PMCID: PMC7051599. 332
13. Moret J, Cognard C, Weill A, Castaings L, Rey A. La technique de reconstruction dans le traitement des anévrismes intracrâniens à collet large. Résultats angiographiques et cliniques à long terme. A propos de 56 cas [Reconstruction technic in the treatment of wide-neck intracranial aneurysms. Long-term angiographic and clinical results. Apropos of 56 cases]. *J Neuroradiol*. **1997** Jun;24(1):30-44. French. PMID: 9303942. 334
14. Tumialán LM, Zhang YJ, Cawley CM, Dion JE, Tong FC, Barrow DL. Intracranial hemorrhage associated with stent-assisted coil embolization of cerebral aneurysms: a cautionary report. *J Neurosurg*. **2008** Jun;108(6):1122-9. doi: 10.3171/JNS/2008/108/6/1122. PMID: 18518714. 338
15. Sluzewski M, van Rooij WJ, Beute GN, Nijssen PC. Balloon-assisted coil embolization of intracranial aneurysms: incidence, 341

- complications, and angiography results. *J Neurosurg.* **2006** Sep;105(3):396-9. doi: 10.3171/jns.2006.105.3.396. PMID: 16961133. 342
16. Lawson AL, Chandran A, Puthuran M, Goddard T, Nahser H, Patankar T. Initial experience of coiling cerebral aneurysms using the new Comaneci device. *J Neurointerv Surg.* **2016** Aug;8(8):e32. doi: 10.1136/neurintsurg-2015-011726.rep. Epub 2015 Jul 2. PMID: 26138730. 344
17. Fischer S, Weber A, Carolus A, Drescher F, Götz F, Weber W. Coiling of wide-necked carotid artery aneurysms assisted by a temporary bridging device (Comaneci): preliminary experience. *J Neurointerv Surg.* **2017** Nov;9(11):1039-1097. doi: 10.1136/neurintsurg-2016-012664. Epub 2016 Oct 14. PMID: 27742747; PMCID: PMC5740552. 347
18. Taqi MA, Raz E, Vechera A, Shapiro M, Gupta R, Haynes J, Tausky P, Grandhi R, Riina HA, Nelson PK, Nossek E. Early Experience with Comaneci, a Newly FDA-Approved Controllable Assist Device for Wide-Necked Intracranial Aneurysm Coiling. *Cerebrovasc Dis.* **2021**;50(4):464-471. doi: 10.1159/000514371. Epub 2021 May 10. PMID: 33971661; PMCID: PMC8315690. 350
19. Sirakov SS, Sirakov A, Hristov H, Raychev R. Coiling of ruptured, wide-necked basilar tip aneurysm using double Comaneci technique. *BMJ Case Rep.* **2018** May 18;2018:bcr2017222703. doi: 10.1136/bcr-2017-222703. PMID: 29776934; PMCID: PMC5965769. 354
20. Wessels L, de Vries J, Boogaarts HD. The Comaneci Device for Entering an Acute-Angled Small Feeder during Cerebral Arteriovenous Malformation Embolization: A Novel Technique to Support Microcatheterization. *Neurointervention.* **2020** Jul;15(2):79-83. doi: 10.5469/neuroint.2020.00122. Epub 2020 Jun 23. PMID: 32570303; PMCID: PMC7412652. 357
21. Thiery L, Carle X, Testud B, Boulouis G, Habert P, Tradi F, Reyre A, Lehmann P, Dory-Lautrec P, Stellmann JP, et al. Distal cerebral vasospasm treatment following aneurysmal subarachnoid hemorrhage using the Comaneci device: technical feasibility and single-center preliminary results. *J Neurointerv Surg.* **2022** May 18:neurintsurg-2022-018699. doi: 10.1136/neurintsurg-2022-018699. Epub ahead of print. PMID: 35584908. 360
22. Giorgianni A, Agosti E, Terrana AV, Vinacci G, Nativo L, Valvassori L, Locatelli D, Lanzino G. Comaneci-Assisted Coiling Embolization of a Posttraumatic Carotid-Cavernous Fistula. *World Neurosurg.* **2020** Sep;141:166-170. doi: 10.1016/j.wneu.2020.05.185. Epub 2020 May 29. PMID: 32474096. 364
23. Chalouhi N, Starke RM, Koltz MT, Jabbour PM, Tjoumakaris SI, Dumont AS, Rosenwasser RH, Singhal S, Gonzalez LF. Stent-assisted coiling versus balloon remodeling of wide-neck aneurysms: comparison of angiographic outcomes. *AJNR Am J Neuroradiol.* **2013** Oct;34(10):1987-92. doi: 10.3174/ajnr.A3538. Epub 2013 May 2. PMID: 23639562; PMCID: PMC7965428. 367
24. Cottier JP, Pasco A, Gallas S, Gabrillargues J, Cognard C, Drouineau J, Brunereau L, Herbreteau D. Utility of balloon-assisted Guglielmi detachable coiling in the treatment of 49 cerebral aneurysms: a retrospective, multicenter study. *AJNR Am J Neuroradiol.* **2001** Feb;22(2):345-51. PMID: 11156781; PMCID: PMC7973939. 371
25. Sirakov A, Minkin K, Penkov M, Ninov K, Karakostov V, Sirakov S. Comaneci-Assisted Coiling as a Treatment Option for Acutely Ruptured Wide Neck Cerebral Aneurysm: Case Series of 118 Patients. *Neurosurgery.* **2020** Nov 16;87(6):1148-1156. doi: 10.1093/neuros/nyaa200. PMID: 32453823; PMCID: PMC7666901. 374
26. Molina-Nuevo JD, López-Martínez L, Pedrosa-Jiménez MJ, Juliá-Molla E, Hernández-Fernández F. Comaneci device-assisted embolization of wide-necked carotid aneurysms with an unfavorable ratio. *BMC Neurol.* **2020** Oct 22;20(1):384. doi: 10.1186/s12883-020-01963-2. PMID: 33092561; PMCID: PMC7584075. 377
27. Cai K, Zhang Y, Shen L, Ni Y, Ji Q. Comparison of Stent-Assisted Coiling and Balloon-Assisted Coiling in the Treatment of Ruptured Wide-Necked Intracranial Aneurysms in the Acute Period. *World Neurosurg.* **2016** Dec;96:316-321. doi: 10.1016/j.wneu.2016.09.029. Epub 2016 Sep 16. PMID: 27647035. 380
28. Wang F, Chen X, Wang Y, Bai P, Wang HZ, Sun T, Yu HL. Stent-assisted coiling and balloon-assisted coiling in the 383

- management of intracranial aneurysms: A systematic review & meta-analysis. *J Neurol Sci.* **2016** May 15;364:160-6. doi: 10.1016/j.jns.2016.03.041. Epub 2016 Mar 25. PMID: 27084238. 384
385
29. Consoli A, Vignoli C, Renieri L, Rosi A, Chiarotti I, Nappini S, Limbucci N, Mangiafico S. Assisted coiling of saccular wide-necked unruptured intracranial aneurysms: stent versus balloon. *J Neurointerv Surg.* **2016** Jan;8(1):52-7. doi: 10.1136/neurintsurg-2014-011466. Epub 2014 Nov 26. PMID: 25428449. 386
387
388
389